

The Significance of Cranial Factors in Diagnosis and Treatment with the Advanced Lightwire Functional Appliance

This article has been peer reviewed.

By Gavin A. James, MDS, FDS and Dennis Strokon, DDS

Osteopaths have known for many years that the skull moves in a rhythmic cycle approximately eight to twelve times per minute and that this movement is present throughout life.¹ This idea contradicts current dental thinking, which implies that the skull, at least in adults, is a solid structure acting as a rigid foundation for the facial and dental structures. For the dentist, therefore, there are two obvious questions. First, does the skull really move in this way and if it does, what, if any, significance does this have for the dental profession?

The original work in this field was done by an osteopath, Dr. William Sutherland, starting in 1910. Over three decades, he studied the question intensely and carried out many experiments, mostly on himself. As a result of his investigation, he began to achieve some remarkable results and started to teach his ideas and methods in the 1940's. Sutherland himself wrote very little,² although there are several compilations of his lectures.^{3,4} The "bible" on the subject was written by one of his students, H. Magoun.⁵ Interestingly, Magoun was aware of possible dental implications and published several articles relating to dentistry.^{6,7,8} These were published in the osteopathic literature and understandably did not come to the attention of the dental profession.

Since then, many osteopaths have addressed the problem of identifying cranial movement and measuring it. There is a substantial body of evidence gathered by Chaitow in his recent book,¹ which devotes several chapters to reviewing the literature. His book is an excellent summary of past and current research. Many of the articles are reports based on manipulative technique, but there are also articles describing the use of various recording devices placed on the skull, for example, transducers for measuring skull movement⁹ or infra-red markers on the skulls of both children and adults allowing a three dimensional kinematic film recording of the skull's movement.¹⁰

An important point to make is that the cranial sutures remain open even in the elderly.¹¹ Closure can occur later in life, but this is considered as a pathological change. Retzlaff has reported that the collagen to elastin ratio is lower in older primate sutures¹² including humans¹³ than it is in younger specimens. In other words, the sutures do not

become stiffer with age, but looser. Mitchell¹⁴ theorizes that this is to compensate for the decreased plasticity of the bones themselves.

The continuing presence of the sutures in the adult skull is one of the best arguments for cranial movement since these would be obliterated if there were not some ongoing function. The sutures contain an extension of the periosteum of the outer layer of the skull as it passes through the suture to become the dural membrane within the skull.¹⁵ The sutures also contain blood vessels, nerves and Sharpey's fibres.¹⁶ Movement across any one suture is very small, but the total effect of the combined movement of the sutures is to give a detectable flexibility. The anatomy of each suture reflects what is occurring along that suture. There are over one hundred and twenty sutures in the cranium and facial structures. These have recently been described in exhaustive detail by Pick,¹⁷ based on many hours of anatomical dissection.

Osteopaths have developed a specific terminology for cranial movement and this will be used throughout the article. In the midline of the skull, there are four bones (Figure 1); the occiput, sphenoid, ethmoid and vomer. The vomer and the central portions of the other three bones move in a vertical plane. The basilar part of the occiput and the basi-

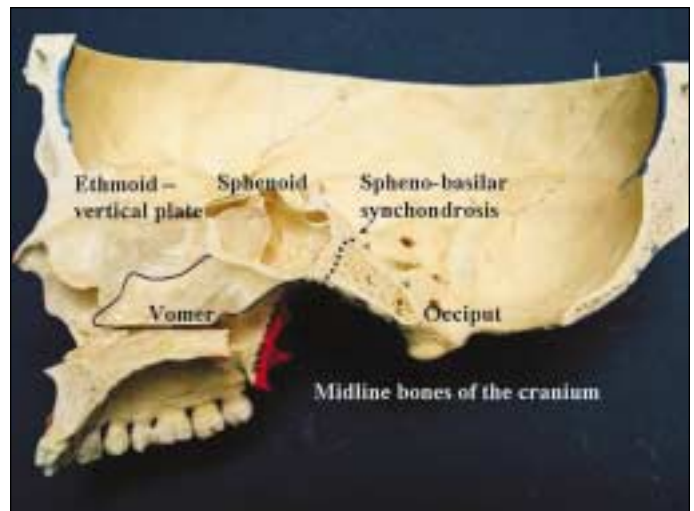


Figure 1

lar portion of the sphenoid bone come together at the sphenobasilar synchondrosis. This is a cartilaginous joint, until approximately twenty-five years-of-age, when the suture becomes fused. In the classical description of cranial motion,⁴ in what is called flexion (Figure 2), the basi-sphenoid and basi-occiput move upwards at the suture. The posterior part of the occiput or squamous portion, flares down as the basi-occiput rises. Similarly, as the basi-sphenoid is elevated, a rotary motion takes place through the body of the sphenoid. On completion of the upward movement, the reverse takes place with the basi-occiput and basi-sphenoid being projected downwards. This is called extension (Figure 3). This process of flexion and extension takes place approximately eight to twelve times per minute.⁵ As the sphenoid rotates in flexion, it carries the pterygoid processes downwards, outwards and slightly backwards. The reverse movement occurs in extension.

These movements all take place in a vertical plane. The peripheral portions of these bones and the lateral bones of the skull move in a lateral plane (Figure 4). In flexion, the skull shortens anteroposteriorly while widening laterally. In

extension, the reverse takes place. There is strong evidence in the osteopathic literature that this movement occurs even in elderly adults.¹ The fact that the sphenobasilar synchondrosis fuses in young adults and yet the cranial movement continues is a source of some disagreement in the osteopathic literature.¹

There are various theories as to what stimulates this movement. One of the most popular is that of Upledger.^{18,19} Cerebrospinal fluid is constantly being secreted by the third and fourth ventricles of the brain. According to Handoll,²⁰ at any one time, there are approximately 140ml of this fluid present in the system with a total of more than 500ml being produced over twenty-four hours. Milne²¹ agrees with Handoll as to the amount of fluid present in the system, but claims that daily production is some 800ml. In any event, it represents a considerable turnover of cerebrospinal fluid. Upledger suggests that as the intracranial pressure within the system rises it stimulates the contraction of the intracranial membrane system. This pushes the fluid through the intracranial spaces and down the spinal cord. Upledger describes it as a semi-closed hydraulic system.

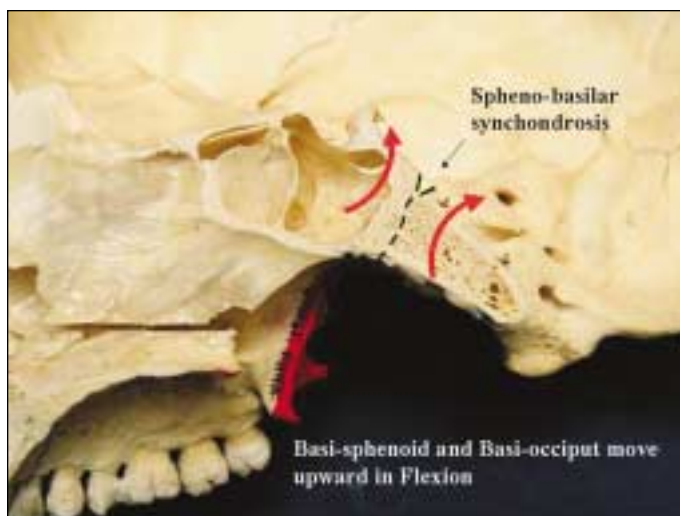


Figure 2

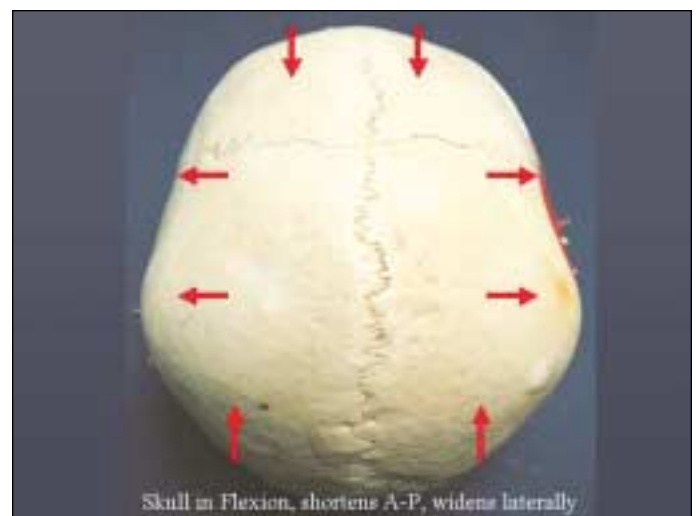


Figure 4

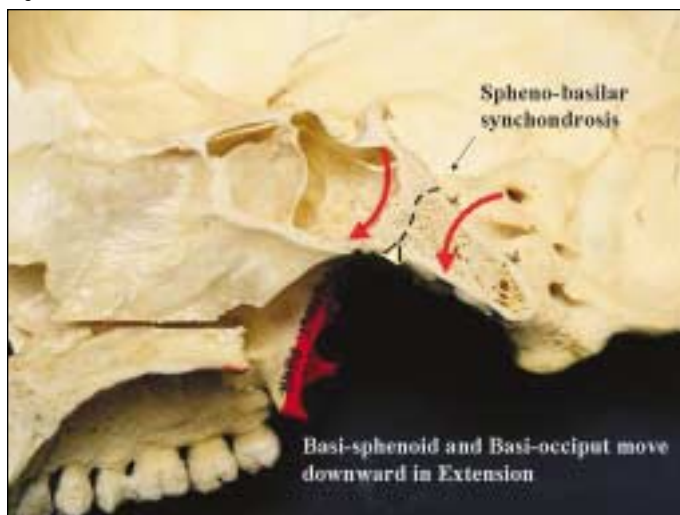


Figure 3

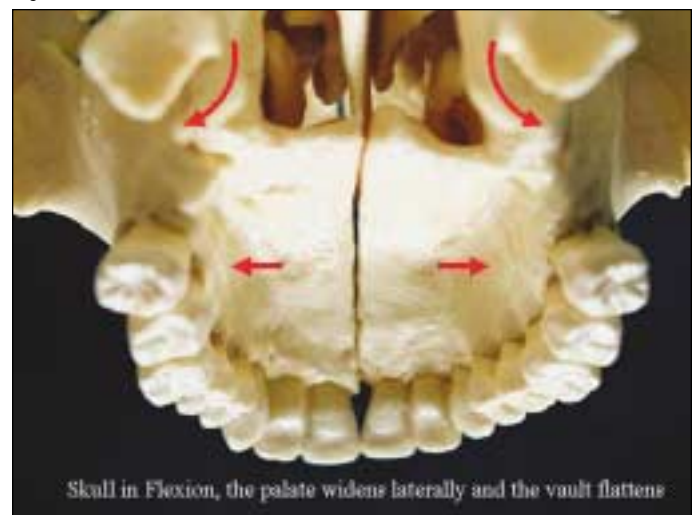


Figure 5

In the mainstream dental literature there are only a few articles describing the effect of this cranial movement on the facial structures and on the dentition.^{22,23,24} The movement of the sphenoid is transmitted throughout the whole spheno-maxillary complex. In flexion, the movement of the pterygoid processes downward and outward affects the palato-maxillary complex. This results in a widening, descending and flattening of the palate (Figure 5). This is followed by contraction and elevation of the palate during the extension phase. Baker, in a meticulous study,²⁵ reported on permanent expansion of the maxillary arch as a direct result of cranial adjustments by an osteopath. The temporal bone also moves around an axis extending from the external auditory meatus to the medial tip of the petrous part of the temporal bone (Figure 6). This carries the glenoid fossa slightly posteromedially in flexion while the squamous portion of the temporal bone flares anterolaterally. In extension, the fossa is carried slightly anterolaterally.

At this point, some of the implications of cranial movement for the dentist become evident. The maxillae have to be seen as two separate bones flexing downwards and out-

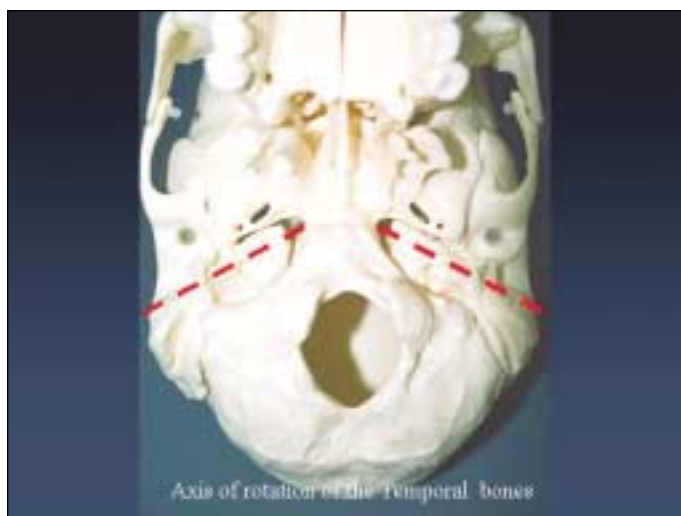


Figure 6

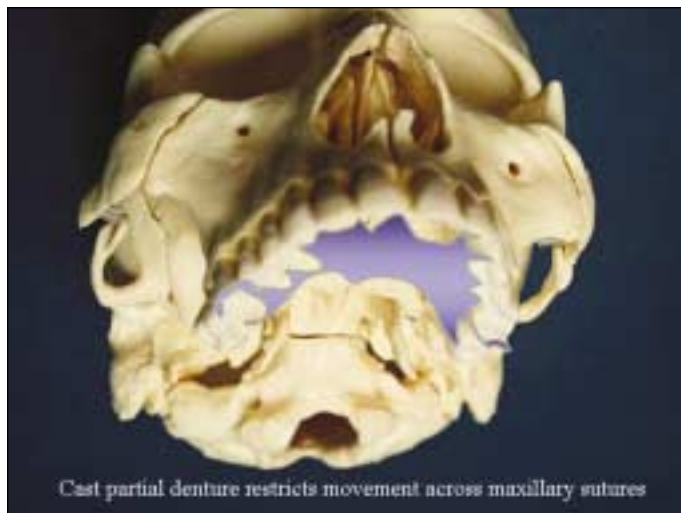


Figure 7

wards then contracting again. Any structure crossing the midline, for example, a cast partial denture, has the potential to restrict this movement (Figure 7). Similarly, a prosthesis crossing the midline in the anterior region should allow some flexibility between the two halves. For the restorative dentist, failure to recognize this movement can create many physical complications and even prosthesis failure. Locking up the maxillae may lead to headaches or facial pain among other symptoms. An assessment of any temporomandibular joint disorder must consider that the glenoid fossa is a flexible mobile structure under the influence of temporal bone orientation within the cranial mechanism.

So far, what has been described is the normal physiological process of cranial movement, i.e., flexion and extension, which continues throughout life. The second concept arising from this work is that distortion can occur across the sphenobasilar synchondrosis, generally at birth,²⁶ but occasionally later due to trauma. In a classic paper,²⁷ Frymann, an osteopath, reports her findings on the skulls of 1,250 newborn infants. In almost ninety percent she discovered obvious distortions of the cranium. This is understandable given the trauma of birth and the necessary flexibility of the cranium to allow passage through the birth canal. However, in many instances, the distortions imposed on the cranium at birth do not resolve spontaneously with time. Frymann described these distortions using the terminology developed by Sutherland.⁴ The basic patterns are hyperflexion, hyperextension, superior vertical strain, inferior vertical strain, torsion and sidebend (Figure 8).

There are only two articles we could find which examine the association of cranial lesions and radiographic evidence. Work by Greenman²⁸ suggests a strong correlation between osteopathic identification and actual cranial morphology, but only twenty-five subjects were examined. A recent article by Oleski et al²⁹ compared the pre and post treatment radiographs of twelve subjects and demonstrated significant

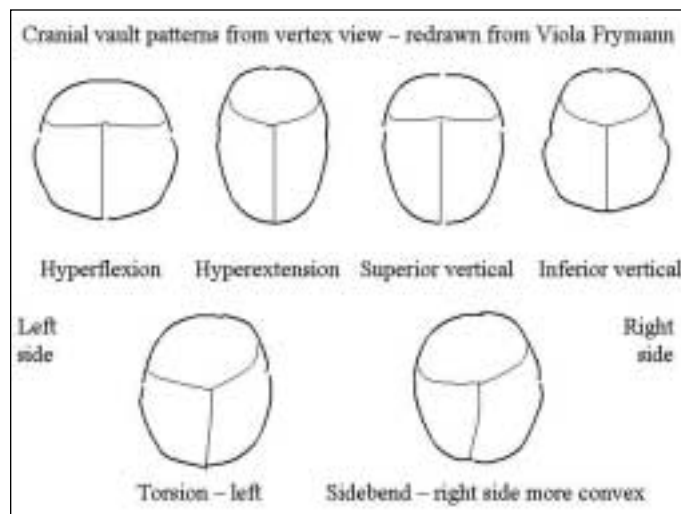


Figure 8: Outlines of Cranial Distortion from Frymann. Figure reproduced by permission of the *Journal of the American Osteopathic Association*.

changes as a result of osteopathic cranial manipulation.

Magoun⁴ describes the distortions of the cranial and facial structures which are associated with each of the different patterns. He mentions dental consequences in passing, but not in detail. There are almost no reports in the dental literature on this topic, except for a number of articles by Jecmen^{30,31,32,33,34} published in specialized journals with a small circulation. Smith, in a thorough presentation, discusses the movement of the cranial bones and the dental implications of this.³⁵ There are also recent articles by Walker,^{36,37} a chiropractor, explaining a chiropractic approach to occlusion and posture.

Based on our studies of the literature and clinical material over a six-year period, we have identified that each of the cranial distortions or "lesions" as the osteopaths call them, predisposes to a specific malocclusion. The cranial lesion is usually the primary etiological factor underlying the different types of malocclusion. Another possibility is that cranial compensation can occur subsequent to temporomandibular joint internal derangement. In this event, the cranial compensation becomes a perpetuating factor that maintains the dental imbalance. Commonly, cranial lesions and temporomandibular joint internal derangements co-exist.

The importance of the airway, tongue behavior, hereditary factors, etc., is acknowledged, but an understanding of cranial lesions puts these into perspective. The significance of this is that by applying appropriate force systems which recognize cranial movement it is possible to achieve correction of the facial structures to an extent well beyond what is currently considered possible.

Osteopaths identify the various cranial lesions primarily by palpation. This skill can be acquired with suitable instruction and practice, but it is possible, by using a combination of clinical observation, radiographic evidence and articulator mounted study models, for a dentist or orthodontist to identify these lesions. Having done so, an approach to treatment involves firstly, correction of the cranial lesions as far as this is possible, then correction of the maxilla and maxillary dentition to the cranium, and finally, correction of the mandible to the maxilla. For many patients the most effective approach is a combination of cranial adjustment by an osteopath or a therapist with cranial skills in conjunction with light orthopaedic-type forces delivered by suitable orthodontic appliances.^{38,39,40} These appliances are discussed elsewhere.⁴¹ It is our experience that the force levels presently used in orthodontics can often restrict the cranial rhythm.

The development of functional orthodontics and particularly its emphasis on temporomandibular joint evaluation both in diagnosis and treatment, has had a profound effect on conventional orthodontic thinking. The recognition of cranial movement and its importance in both diagnostic evaluation and the delivery of appropriate forces in orthodontic treatment represent, in our opinion, an even bigger

paradigm shift. It is necessary to recognize the growing influence of these concepts not only in the osteopathic profession, but also in physiotherapy, massage therapy and chiropractic as well as dentistry. Courses in cranial osteopathy are available for dentists and doctors.⁴² However, it is not essential to have skills in cranial osteopathy to start using the underlying principles in diagnosis and treatment of orthodontic problems.

Cranial osteopathy represents a truly revolutionary idea for dentistry since it is based on concepts of functional anatomy and cranial motion which are not recognized in current dental thinking. We are convinced that an understanding of cranial movement together with the use of appliances specifically designed to change cranial, facial and dental structures, represent a profound, exciting and innovative development in orthodontics. Incorporating cranial assessment into practice requires additional viewing and measurement of dental structures. The patient has to be seen from a wider perspective than is usual. In addition to conventional orthodontic diagnosis patients are further assessed by osteopathic description to categorize and explain their cranial and dental configuration. Having established an osteopathic description of the patient's cranial pattern, the extent of the dental problem may be truly appreciated. The importance of recognizing dental effects resulting from cranial distortion is illustrated in the following case reports.

History Case # 1

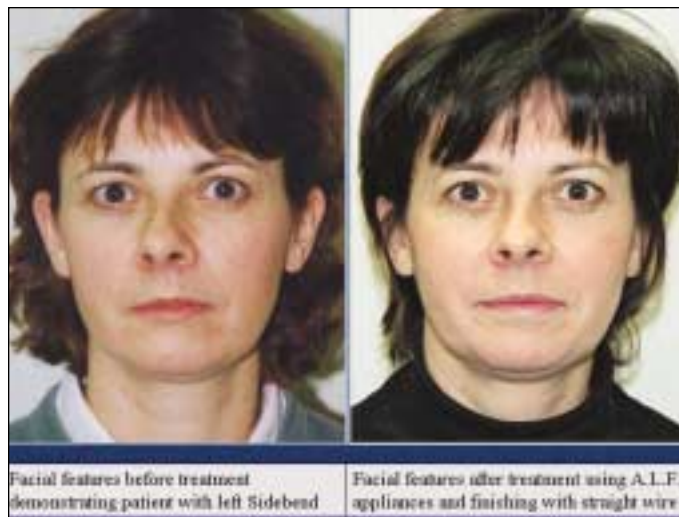

Figure 9A

Figure 9B

Patient: K.M. Thirty-eight year-old female (Figure 9A).

History: The patient's chief complaint was the appearance of her teeth. The missing upper right second bicuspid was replaced by fixed bridge seven years prior to her request for orthodontic treatment.

Other symptoms were mild and included occasional clicking of the right TM joint and occasional headache.

Diagnosis: The dental malocclusion is described as a Class

II/Division I with an anterior open bite (Figure 10a, b, c). The cephalometric readings indicate an excessive A-B distance when measured in a horizontal plane. The pattern is of a severe Skeletal Class II with an anterior tongue thrust. The malocclusion is complicated by the asymmetry of the dentition. There is a Class I molar relationship on the right and Class II on the left. The maxillary and mandibular center lines are off, with displacement of the maxillary arch to the right and the mandibular arch to the left. There is lateral constriction of both arches with the periodontium on the labial aspect of the mandibular anteriors being fragile.

A less than ideal result following orthopaedic and orthodontic correction was anticipated in view of the severe anteroposterior discrepancy. It was explained to the patient that surgical correction of the Class II problem might be required given her age and the severity of the discrepancy. The patient declined surgical correction.

The osteopathic description is of a left sidebend. There are several components to a sidebend, but the key factors are as follows:

- If a vertical axis is imagined through the sella turcica of the sphenoid and one through the middle of the foramen magnum of the occiput, the two bones rotate around the vertical axes away from each other to give a characteristic shape of the cranium. The left side of the head becomes longer and more convex. There is a corresponding shortening and concavity on the right side. The vertex view of a sidebend is illustrated in Figure 8, but note that this is for a right and not a left sidebend as is the case here.
- As the left greater wing of the sphenoid swings forward and rotates to the right, it carries the maxilla with it. As the occiput rotates distally, it carries the temporal bone together with the glenoid fossa distally. This brings the mandibular condyle back on the left with the chin subsequently swinging to the left.
- The pre-treatment photograph (Figure 9a) illustrates the facial effects. The nose and the philtrum of the lip are deviated to the right while the chin is displaced to the left.

Treatment: The first phase of treatment was aimed at correcting the lateral contraction of the maxilla and mandible and levelling the maxillary cant up to the left. As this was developed, the rotation of the maxilla and the mandible towards the mid-line was undertaken by placement of light Class III elastic forces on the right side (opposite sidebend) and Class II elastics forces on the sidebend side. Advanced Lightwire Force (ALF) appliances were used. The severe crowding of the mandibular anterior segment was relieved by use of a lip bumper attached to the ALF appliance.

Once the lateral distortions and rotation of the arches had been corrected the Class II problem was treated by Twin Block appliances constructed on an ALF framework. Final alignment of the teeth was done with straight wire brackets and arches.

Results: Results achieved by use of ALF appliance therapy are dramatic both from a dental and orthopaedic aspect.

Facially, there has been centering of the nose and philtrum. The chin is also centered and the cant of the lips up to the left has been leveled (Figure 9B).

Dentally, there has been correction of the center lines with reduction of the overjet (Figure 11a, b, c). The occlusion is now an Angle Class I both in terms of the molar and cuspid relationship. Despite the severe pre-treatment lateral contraction of both arches, there has been good lateral development without loss of the supporting alveolar bone. In particular, the healthy appearance of the periodontal tissues around the mandibular anterior teeth should be noted.

Conclusions: Treatment was over a four-year period. This is unusually lengthy, but reflects the severity of the underlying skeletal and dental discrepancies. One

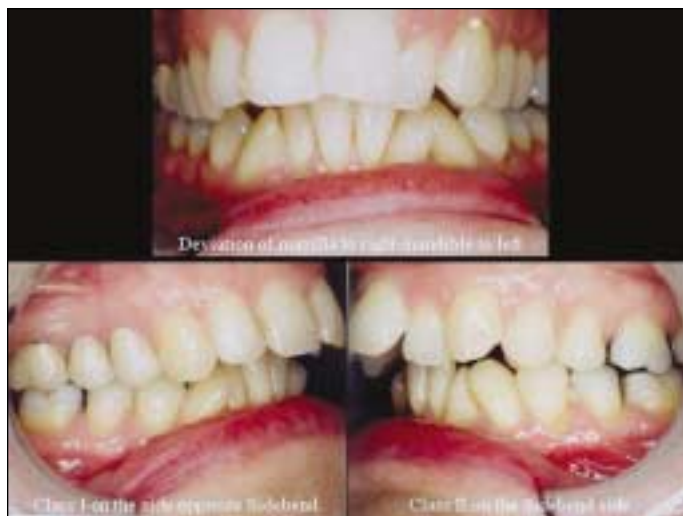

Figure 10A, B, C

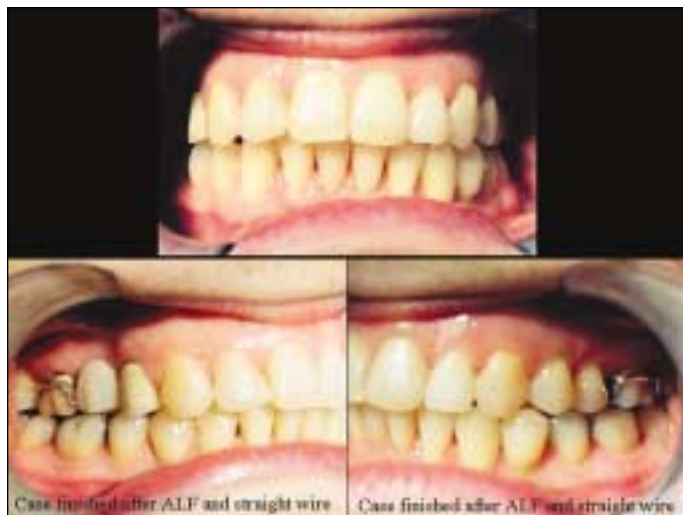

Figure 11A, B, C

advantage to the time factor was to allow development of the alveolar bone to ensure healthy periodontium. It also helps to develop stability following retention.

History Case #2

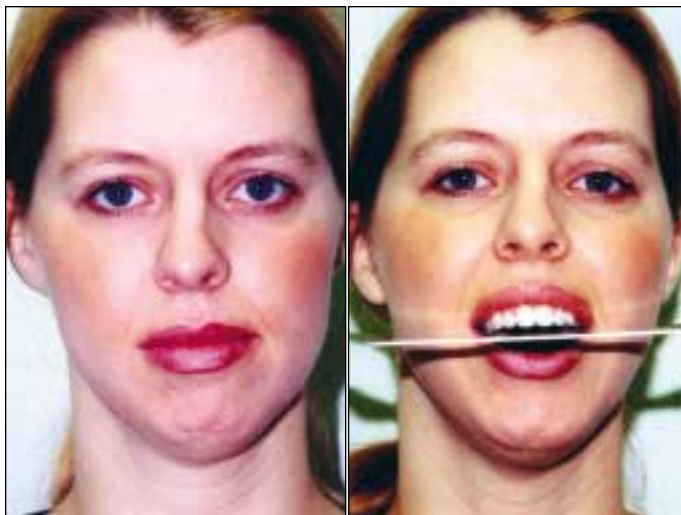

Figure 12A

Figure 12B

Patient: C.B. Twenty-six year-old female (Figure 12A).

History: Headaches for the past ten years. Headaches have been persistent for the past three years. Other symptoms include facial pain, especially over the left temporomandibular joint, bilateral reciprocal clicking of the temporomandibular joint and extensive myofascial pain throughout the face and head. There has been recent onset of diaphragmatic breathing problems and episodes of dizziness.

The chief complaint is of headaches and inability to continue her career as an opera singer because of breathing difficulty. There is a history of severe bruxing, head trauma at age 23 and Bell's palsy at age 20.

Previous treatment included orthodontic treatment from age 13 to 19. Treatment included wearing a gear-activated acrylic plate to widen the maxillary arch, a course of treatment in fixed braces, and an appliance worn at night to advance the lower jaw position.

At the time of the most recent diagnosis the patient was aware that the upper right quadrant was collapsing inward toward the palate. She was required to move her jaw to the left in order to occlude her teeth.

Diagnosis: In dental terms, there is an Angle Class I with lower incisor proclination. The discs are displaced anteriorly with luxation of both condyles in occlusion. The luxation is reduced on opening.

In osteopathic terms, there is a left torsion. This means that in an anteroposterior axis from between the eyes to the posterior edge of the foramen magnum the sphenoid rotates around this so that the left greater wing goes up, carrying the orbit and the left maxilla with it. This gives a characteristic facial appear-

ance of the ocular and occlusal planes running upward to the left in parallel.

Treatment: Advanced Lightwire Functional Appliances were used to free up the maxilla, intrude the maxillary right buccal segment and extrude the left maxillary buccal segment. These appliances included a pad over the right posterior mandibular teeth and vertical elastics from the first maxillary and mandibular molars on the left. Adjunctive osteopathic adjustments were made over the course of treatment.

Results: Over a nine-month period, the maxillary plane was completely leveled and the ocular plane also responded. All symptoms were resolved. The bruxing pattern ceased and the myofascial tenderness disappeared. The eyes are now level as well as the maxillary plane. The relationship of the maxilla to mandible is corrected so that both the maxilla and mandible are aligned with the facial midline (Figures 13A and 13B).

Conclusions: In osteopathic terms, bruxing and clench-

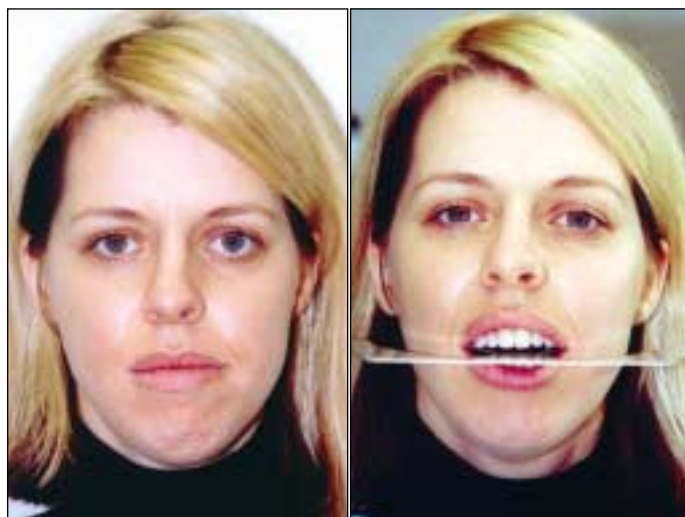


Figure 13A

Figure 13B

ing represented a subconscious attempt by the body to level the head using the mandible as a platform from which to exert force, i.e., the needs of the cranial mechanism dominated to the point of creating dysfunction of the temporomandibular apparatus. The temporomandibular joint and myofascial signs and symptoms were as a result of the intense force generated.

Correction of the left torsion of the sphenoid, i.e., bringing the greater wing down, removed the need for the compensatory adaptive patterns. The health of the cranial mechanism and its normal function is central to the overall health of the body.

Summary

These two cases have been chosen to illustrate the very considerable potential for change once the cranial lesions have been identified and their correction is planned as part of treatment.

References

1. Chaitow, Leon, *Cranial Manipulation, Theory and Practice*, Churchill/Livingstone 1999.
2. Sutherland, W., *The Cranial Bowl: A Treatise Relating To Cranial Mobility, Cranial Articular Lesions and Cranial Technique*. Edition 1, Free Press Co., Mankato, Minn. 1939.
3. Sutherland, W., *Contributions of Thought, Collected Writings*. Edited by Wales, A.L. Sutherland Cranial Teaching Foundation, 2nd Edition 1988.
4. Sutherland, W., *Teachings in the Science of Osteopathy*. Sutherland Cranial Teaching Foundation 1990, Edited by Wales, A.L.
5. Magoun, H.I., *Osteopathy in the Cranial Field*. 3rd Edition. 1976. Available from Sutherland Teaching Foundation, 4116 Hartwood Drive, Fort Worth, TEXAS. 76109.
6. Magoun, H.I. Dental Equilibration and Osteopathy. *JAOA*, Volume 74, June, 1975, pages 981-991.
7. Magoun, H.I., Osteopathic Approach to Dental Enigmas. *JAOA*, Volume 62, Pages 110-118, October, 1962.
8. Magoun, H.I., Ideopathic Adolescent Spinal Scoliosis. *The D.O.*, Volume 13, Pages 6-13, 1973.
9. Frymann, V., A Study of the Rhythmic Motions of The Living Cranium. *JAOA*, Volume 70, Pages 928-945, 1971.
10. Zanakis, M., Zaza, B., Objective Measurement of Cranial Rhythmic Impulse in Children. *JAOA*, Volume 96, No.552, Page 5.
11. *Grays Anatomy*, 35th Edition, 1973, Longman.
12. Retzlaff, E., Aging of Cranial Sutures in Macaca Nemestria. *Anatomical Records*, page 520, 1978.
13. Retzlaff, E., Aging of Cranial Sutures in Humans. *Anatomical Records*, Page 663, 1979.
14. Mitchell, F.L., Personal Communication. December, 1986.
15. Retzlaff, E., The Cranium and its Sutures. Published by Mitchell, F.L., Springer, Verlag. 1987.
16. Pritchard, J.J., Scott, J.H., Girgis, F.G., The Structure and Development of Cranial and Facial Sutures. *Journal of Anatomy*, Volume 90, pages 73-86, January, 1956.
17. Pick, Marc, *The Cranial Sutures: Analysis, Morphology and Manipulative Strategies*. Eastland Press Inc., Seattle, WA, 1999.
18. Upledger, J., Vredevoogd, J.D., *Craniosacral Therapy*. Eastland Press, 1983.
19. Upledger, J., *Craniosacral Therapy II: Beyond the Dura.*, Eastland Press, 1987.
20. Handoll, N., *The Anatomy of Potency*. Osteopathic Supplies, Ltd., 2000. Distributed in NA by Stillness Press LLC., Phone: 503-265-5002.
21. Milne, Hugh, *The Heart of Listening: A Visionary Approach to Craniosacral Work*. North Atlantic Books, Berkeley, CA, 1995.
22. Blood, Stephen D., The Craniosacral Mechanism and The Temporomandibular Joint. *JAOA*, Volume 86:8, Pages 512-519, 1986.
23. Gillespie, B.R., Dental Considerations of the Craniosacral Mechanism. *Journal of Cranio-Mandibular Practice*, Volume 3, No. 4, Page 380, 1985.
24. Harakal, John, Manipulative Medicine in Dentistry: A New Potential for Diagnosis and Treatment. *Journal of Cranio-Mandibular Practice*. Volume 3, No. 1, Page 63. Dec, 1984 – February, 1985.
25. Baker, E.G., Alteration in width of the maxillary arch and its relation to sutural movement of cranial bones. *Journal of American Osteopathic Assoc.*, Vol.70, Pg. 559-564, 1971.
26. Frymann, V., The Trauma of Birth. *Osteopathic Annals*, Pages 197-205, May, 1976.
27. Frymann, V., Relation of Disturbances of Craniosacral Mechanisms to Symptomatology of the Newborn: Study of 1,250 Infants. *JAOA*, Volume 65, Pages 1059-1076, 1966.
28. Greenman, P.E., Roentgen Findings in the Craniosacral Mechanism. *JAOA*, Volume 70, Pages 60-71, 1970.
29. Oleski, S.L., Smith, G.A., Grow, W.T., Radiographic Evidence of Cranial Base Mobility. *Journal of Cranio-Mandibular Practice*, Volume 20, pages 34-38, 2002.
30. Jecmen, J.M. "Sidebending Rotation from a Dental Perspective." *The Cranial Letter*, The quarterly Newsletter of the Cranial Academy, Volume 44, Winter, 1991.
31. Jecmen, J.M., "Dental Support for the Temporal Bone. *The Cranial Letter*, Volume 47, Winter, 1994.
32. Jecmen, J.M., "The Temporal Bone as it Relates to Occlusion." *Cranio-View*, Volume 3, Sept. 1994.
33. Jecmen, J.M. "Understanding Malocclusion," *Cranio-View*, Volume 4, June, 1995.
34. Jecmen, J.M., "Interfacing Osteopathy in the Cranial Field, Craniofacial Orthopaedics And Orthodontics." *The Cranial Letter*, Volume 51, February, 1998.
35. Smith, G.H., Dental Implications of Cranial Osteopathy. *Journal of General Orthodontics*, Nov./Dec. 1985, Pages 34-44.
36. Walker, J., Chirododontics – A Treatment Paradigm For The New Millenium. *Functional Orthodontist*, Nov./Dec. 1998. Pages 12-15.
37. Walker, R., Looking at Cranial Distortions. *Functional Orthodontist*, Spring 2001. Pages 15-20.
38. Nordstrom, D., Positive Alveolar and Gingival Effects Of the ALF Appliance. *Functional Orthodontist*, Nov./Dec. 1996. Pages 4-6.
39. Smith, G.H., Ashton, A., ALF (Advanced Lightwire Functional) Reduces Orthodontic Relapse Factor. *The Functional Orthodontist*, Nov./Dec. 1996. Pages 16-20.
40. Smith, G.H., Ashton, A. Alternative Lightwire Functionals (ALF). *The Functional Orthodontist*. Sept./Oct. 1995. Pages 35-38.
41. James/Strokon Seminars. Information from: Telephone: (705) 721-0350, Fax: (705) 721-8153.
42. The Cranial Academy. Component Society of the American Academy of Osteopathy. Telephone: (317) 594-0411, Fax: (317) 594-9299.



Gavin A. James, MDS, FDS

Dr. James is an Orthodontic Specialist in Barrie, Ontario. A major part of his practice is concerned with the management of temporomandibular joint and craniomandibular disorders. His interest in cranial movement has developed as a part of a more comprehensive examination of the problem of head and neck pain.



Dennis Strokon, DDS

Dr. Strokon is a general dentist in Ottawa, Ontario. He received his dental degree from the University of Western Ontario in 1972. For the past twenty-five years he has taken an interest in treating symptomatic patients using both restorative and orthodontic techniques in his practice. Dr. Strokon and Dr. James lecture on the philosophy, treatment concepts and design of the ALF appliance. They will be presenting a session at the IAO's annual meeting in Savannah, Georgia in 2004.